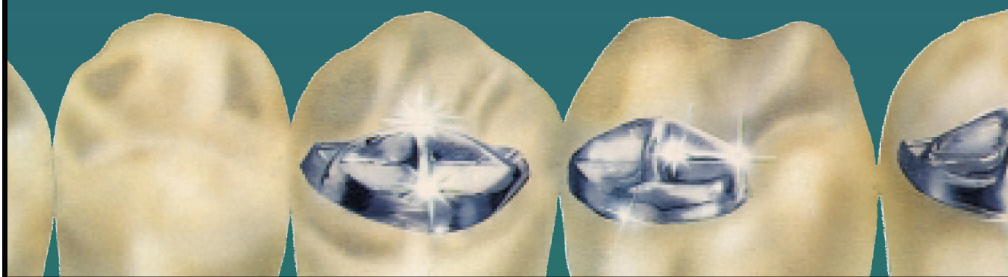


**Lingual
Bladed
Teeth
by Levin
Manual**



Lingual Bladed Teeth by Levin

- Provide maximum chewing efficiency plus the esthetics of natural teeth.
- Are articulated to achieve bilateral balance in most clinical situations.
- Can be used for lingualized occlusion or monoplane (flat teeth) occlusion.
- Are manufactured with color-stable, cross-linked acrylic resin, unbreakable cast chrome alloy blades, and in a variety of popular shades.

Patients and dentists have been aware of the limitations of artificial teeth for a long time. In 1895, G. V. Black¹ invented a gnathodynamometer to measure a wide range of chewing forces for various types of food. These forces varied from 5 to 175 pounds. Black found that denture patients used chewing forces of only 20 to 30 pounds because of pain or fear of pain. It is not surprising that Manley² and Kapur and Soman³ conducted chewing tests and found that artificial dentures were only one sixth as efficient as natural teeth.

The difference in efficiency between natural and artificial teeth is obvious. Natural teeth have crowns which are supported by roots, periodontal ligaments, and bony sockets. Artificial teeth are supported by a soft thin layer of oral mucosa that rests on a bony ridge, which cannot provide the sturdy support available to the natural teeth. Because of this difference, it is illogical to use the natural tooth forms for denture teeth.

Mechanical Teeth

After many disappointing experiences, various dentists abandoned the concept of the natural tooth form and designed mechanical tooth forms to improve chewing efficiency. Hardy⁴ designed a serpentine-like, cast metal ribbon which protruded about 1mm from the occlusal surfaces of flat resin teeth. Cook⁵ designed the Masticators: flat, cast metal mandibular teeth, except for the first bicuspid, which had sharp buccal cutting edges created by holes on the occlusal and buccal. Bader⁶ designed the Cutter Bar: a sharp-edged, cast mandibular tooth placed in the first molar and second bicuspid area.

The two latter mechanical forms are no longer available. Many other mechanical forms have been designed, but not accepted, all using a monoplane or flat type of articulation. Not only was it impossible to obtain classic bilateral balance with these teeth, but their appearance was often unacceptable to many patients.

Sosin⁷ was the first to design a mechanical tooth that had excellent function and could be set in bilateral balance. He designed a cross-blade of cast chrome alloy, placed on the maxillary denture and opposed by flat areas of occlusion. These were custom made from chrome alloy or resin.

Lingual Bladed Teeth

Levin⁸ was influenced by Sosin's design but was interested in teeth with better esthetics. He made the Sosin blades smaller and placed them on the mesio-lingual cusps of the first and second maxillary molars, and the lingual cusps of the second bicuspid. The teeth are anatomical in form and as such look natural and esthetic. They are designed in a size suitable for most ridges. The maxillary bicuspid has ideal buccal length (9.5mm) for good esthetics. The first bicuspid can be eliminated if a space problem exists. The blades, which show very little or not at all when the patient is talking or smiling, are made of unbreakable cast chrome alloy, with .5mm edges and 2mm long. If desired, the blades can be sharpened with carborundum disks or heatless stones.

Position of the Anterior Teeth

The shape, color, and arrangement of the anterior teeth are very important, as most patients are very concerned about the appearance of these teeth. Frush and Fisher⁹ have offered useful guidelines for their selection and arrangement. Pound¹⁰ has described the phonetic method, i.e., the use of the "F" and "S" sounds, which has proved to be very useful. Incisal guidance is usually determined by the esthetic and phonetic positions of the anterior teeth, but this can often be adjusted if a higher or lower incisal guidance is needed for balance.

Articulation: General Considerations

Best results will be obtained if an adjustable or semi-adjustable articulator, e.g., Hanau H2, Whipmix, etc., is used. It is recommended to use a protrusive interocclusal record or a needle point tracing in order to set the saggittal condyle path. If these records are not taken, it is recommended to set the condyle path at 30° and the incisal guidance at 10° . If the condyle path is recorded and is steeper than 30° , set the incisal guidance at 0° . If the condyle path is 20° , set the incisal guidance at 20° . Also, the compensating curve will vary according to the saggital condyle path. For balance, a steeper path will require the compensating curve to be more pronounced and a lower path will require a flatter curve.

Figure 1

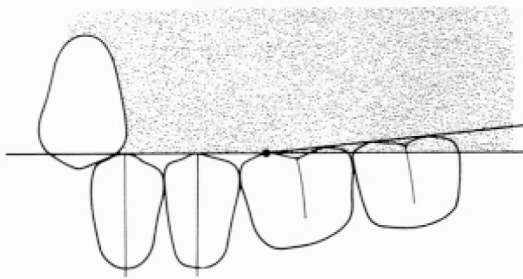


Figure 2

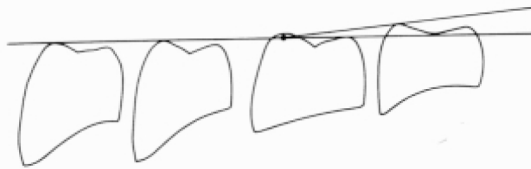


Figure 3

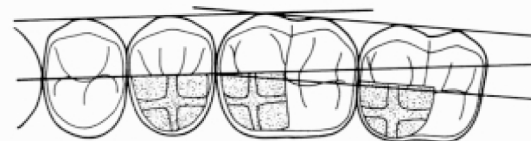


Figure 1: The buccal cusps of the first and second bicuspid should touch the occlusal plane. The long axes are at right angles to the plane.

The buccal cusps of the mandibular molars should be arranged to form an angle of 6° with the occlusal plane, beginning at the mesio-buccal cusp of the first molar. All the buccal cusps of the mandibular molars must touch the 6° plane. If the sagittal condyle path is steeper than average, e.g. 45° , it may be necessary to make the 6° angle steeper, i.e., increase the compensating curve. If the path is shallower, it may be necessary to reduce the 6° occlusal plane angle.

The mandibular molars are designed so that the lingual cusps are a little shorter than the buccal cusps. The maxillary molars are designed so that the lingual cusps are a little longer. This creates the "Curve of Wilson," needed for balance.

Figure 2: This drawing shows a distal view of each mandibular tooth and the relationship of the cusps to the occlusal and 6° planes.

First bicuspid: The buccal cusp is on the occlusal plane. The lingual cusp is slightly below (about $\frac{1}{2}$ mm) the plane.

Second bicuspid: Same as above.

First molar: The mesio-buccal cusp is on the occlusal plane and the disto-buccal cusp is on the 6° plane. The mesio-lingual cusp is slightly below the occlusal plane. The disto-lingual cusp is on the occlusal plane.

Second molar: The buccal cusps are on the 6° plane. The lingual cusps are about midway between the occlusal and 6° planes.

Figure 3: This drawing shows the maxillary teeth set in harmony with the center of wax occlusion rims. The contour of the wax rims and center line are usually determined by the dentist. If not, the dental technician must use anatomical landmarks on the casts, such as bony anatomy, anterior papilla, pear-shaped pad, etc. for determining the center line (tooth position).

The curve of the arch usually breaks the center line at the mesial aspect of the first molar but this may vary depending on the shape of the arch. A square arch will usually have a straight center line. A tapering arch will also usually have a straight center line but it will be more to the buccal.

Figure 4

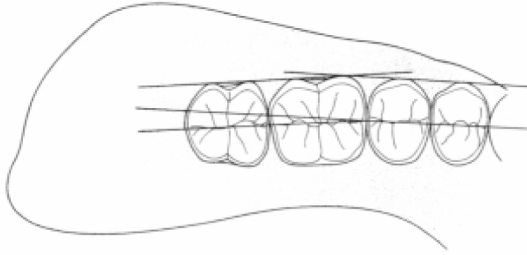


Figure 5

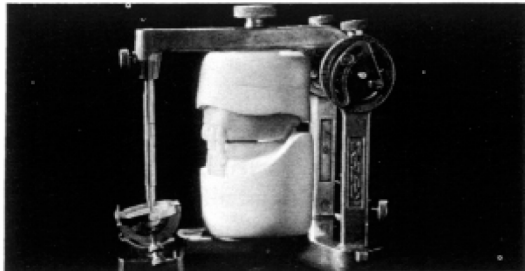


Figure 4: This is an occlusal drawing showing the special anatomy that will articulate correctly with the lingual blades of the maxillary teeth. The remarks made under Figure 3 apply as well to Figure 4. The center of the fossae of the molars should line up with the center of the pear-shaped pad. This is very important for the stability of the mandibular denture.

Articulation of the Teeth

Note: Many instruction books and manuals will recommend that the upper teeth be set first, followed by the lower first molar and then the rest. This has resulted in many dentures with teeth that are too buccal to the ridge. Also, problems in esthetics have occurred because the first bicuspid have had inadequate space or too much. We recommend that the lowers be set first.

Arrange the anterior teeth for correct esthetics and phonetics. 1
Set the incisal table.

Remove sufficient wax from the lower occlusion rim. Do not 2
disturb the upper rim (Figure 5).

Figure 6

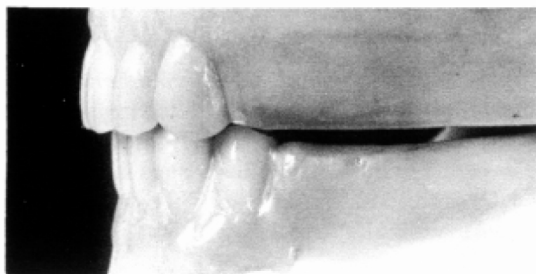


Figure 7

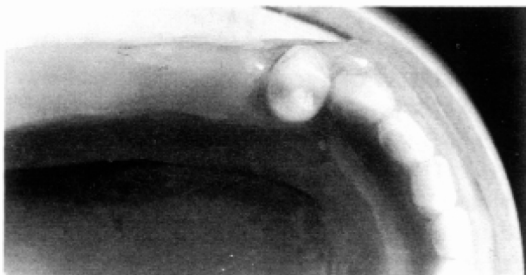


Figure 8

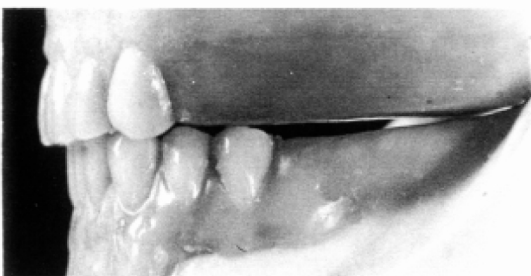
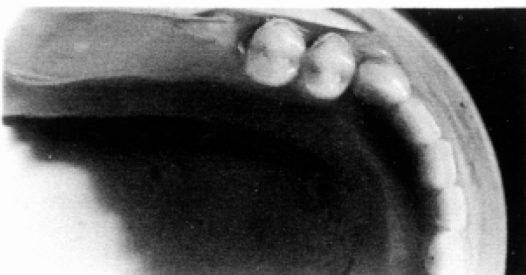
Figure 9



Set the mandibular first bicuspid with the distal slope of the maxillary cuspid. Figure 6 is a buccal view and Figure 7 is a occlusal view. 3

Set the mandibular second bicuspid so it is on the center line and touches the maxillary occlusion rim. Figure 8 is a buccal view and Figure 9 is an occlusal view. 4

Figure 10

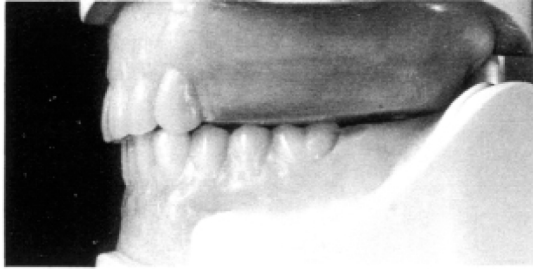

Figure 11

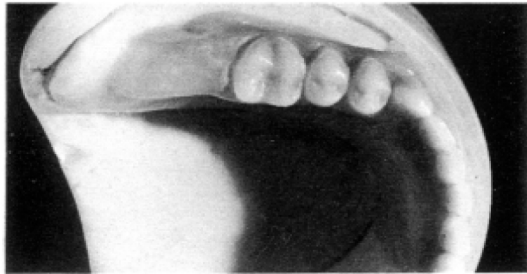
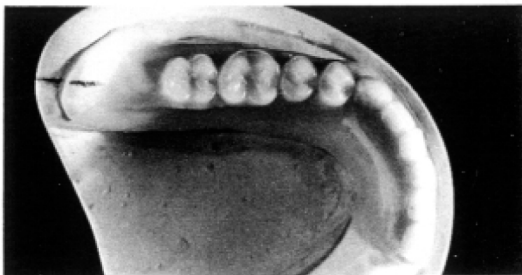


Figure 12

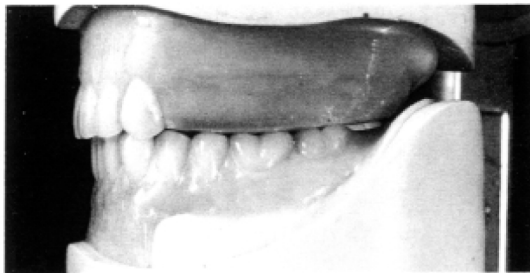

Figure 13



Remove a small amount of wax from the maxillary occlusion rim, simulating the 6° change in the occlusal plane. The amount of wax may be more or less depending on the angle of the condyle path. Place the first mandibular molar so it touches the rim and is in harmony with the center line. Figure 10 is a buccal view and Figure 11 is an occlusal view.

5

Set the mandibular second molar so it touches the maxillary occlusion rim and is in harmony with the center line. *Now* is a good time to make certain that the central fossae of the molars are lined up with the center of the pear-shaped pad. Figure 12 is the buccal view and Figure 13 is an occlusal view.

6

Figure 14

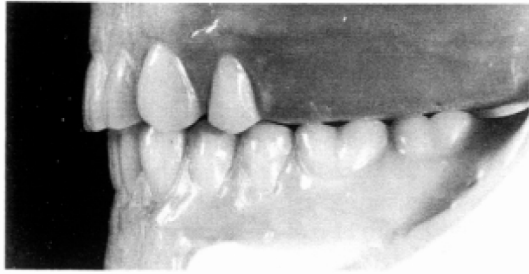

Figure 15

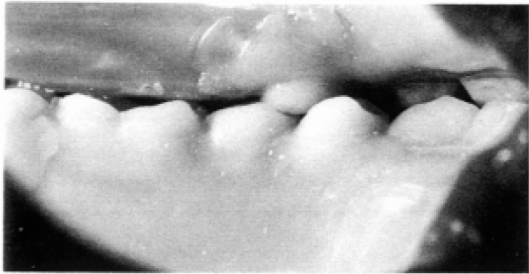

Figure 16

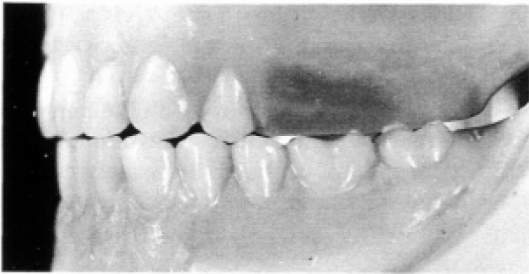
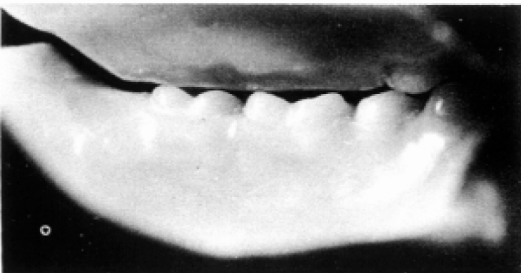

Figure 17



Set the maxillary first bicuspid so it articulates with the mandibular first and second bicuspid. The teeth should be in firm contact in the centric relation position. Figure 14 is the buccal view and Figure 15 is the lingual view.

7

Figures 16 and 17 show the working side balanced occlusion from the buccal and lingual view.

Figure 18

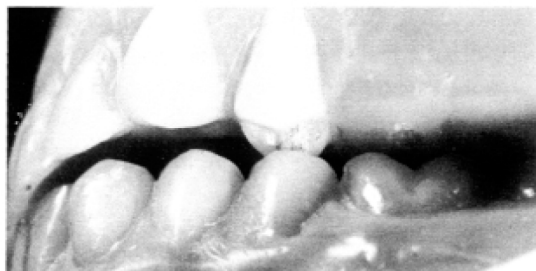

Figure 19

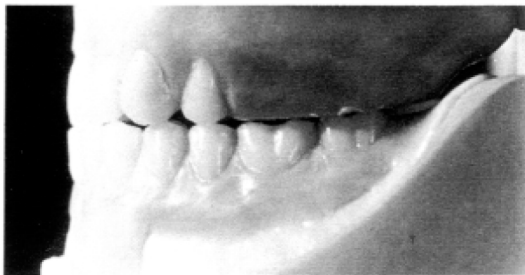

Figure 20

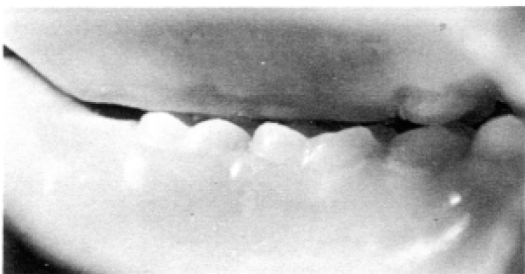

Figure 18 shows a buccal view of the balancing-side balanced occlusion.

Figures 19 and 20 show the protrusive balanced occlusion from the buccal and lingual view.

Figure 21

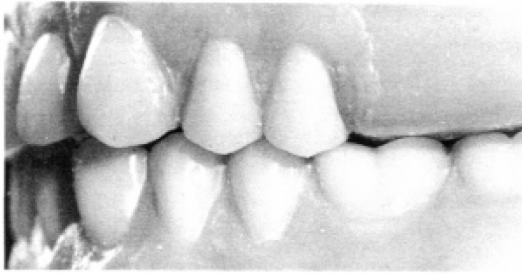

Figure 22

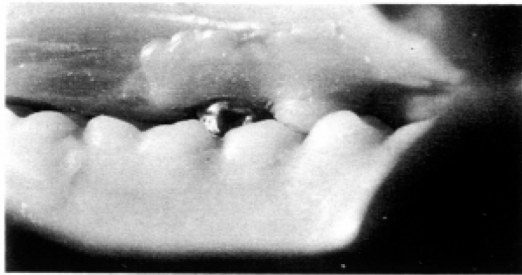


Figure 23

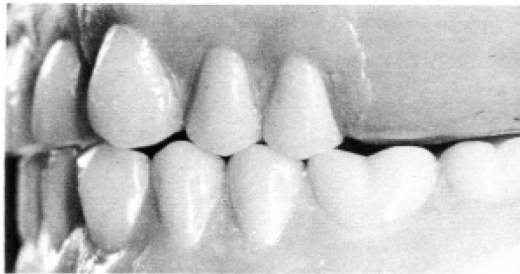
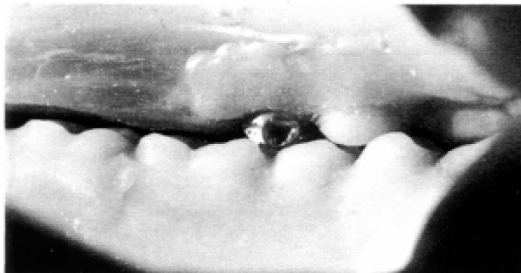

Figure 24



Set the maxillary second bicuspid so it articulates with the mandibular second bicuspid and first molar. The teeth should be in firm contact in the centric relation position. This is also the first bladed tooth. Note how the anatomy has been altered slightly on the distal of the lower bicuspid to accommodate the blade. Slight modifications of the teeth that oppose the blades may be necessary in order to obtain ideal articulation. Figure 21 is the centric relation buccal view and Figure 22 is the lingual view.

8

Figures 23 and 24 show the working-side balanced occlusion from the buccal and lingual views.

Figure 25

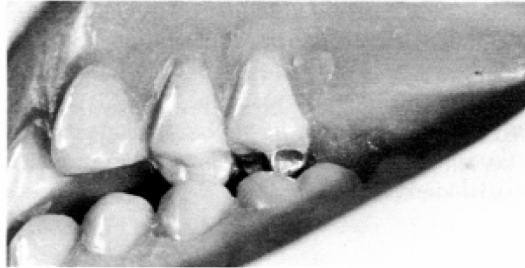


Figure 26

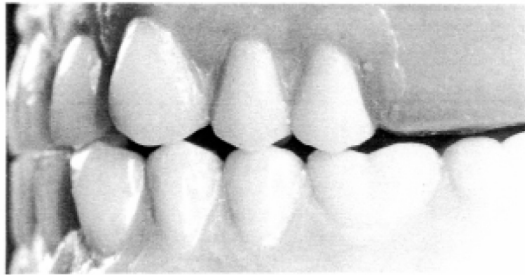


Figure 27

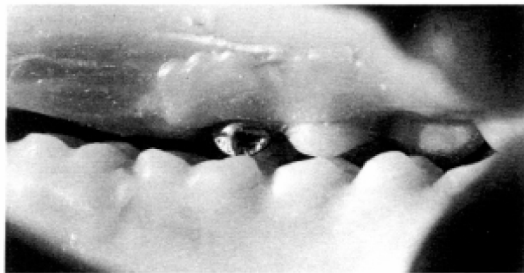


Figure 25 shows a buccal view of the balancing-side balanced occlusion.

Figures 26 and 27 show the protrusive balanced occlusion from the buccal and lingual views.

Figure 28

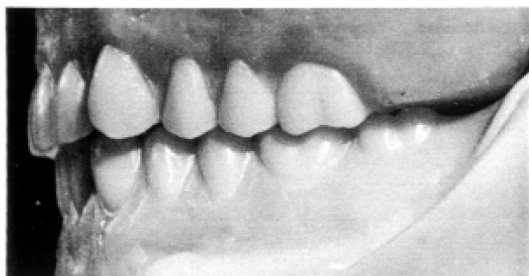

Figure 29

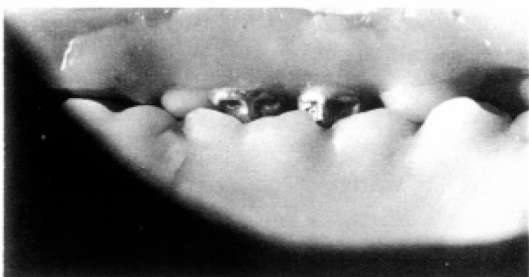

Figure 30

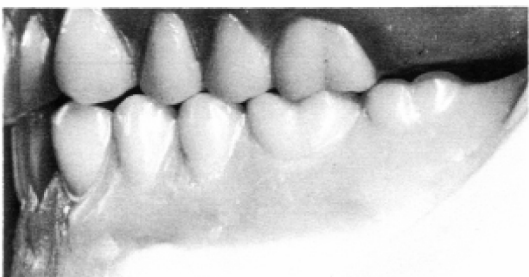
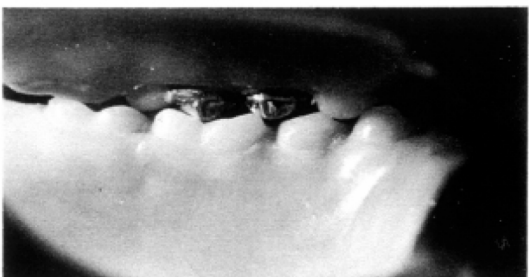
Figure 31



Set the maxillary first molar so it articulates with the mandibular molar. The mesio-lingual blade will fit into the specially designed central fossa of the lower molar. Note the adequate overjet on the molars as well as the bicuspids. This is needed to prevent cheek and tongue biting. The teeth are designed so a tight centric relation occlusion is easily accomplished. Make certain that the mesial cusp of the maxillary molar is lined up correctly with the buccal groove on the lower molar. Figures 28 and 29 show the centric relation occlusion from the buccal and lingual view.

Figures 30 and 31 show the working-side balanced occlusion from the buccal and lingual views.

Figure 32

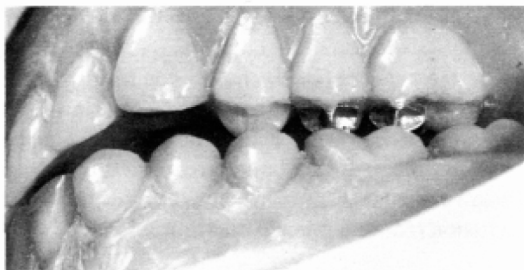

Figure 33

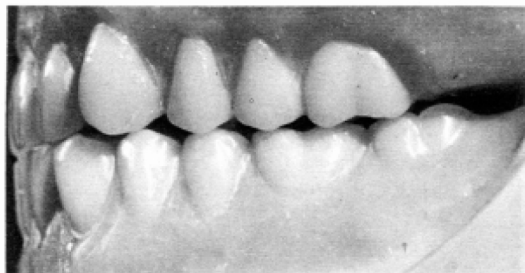

Figure 34

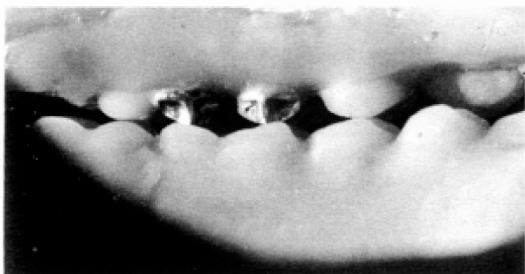

Figure 32 shows the balancing-side balanced occlusion from the buccal view. Balancing contacts are very important for stability, especially during parafunctional movements.

Figures 33 and 34 show the protrusive balanced occlusion from the buccal and lingual view.

Figure 35

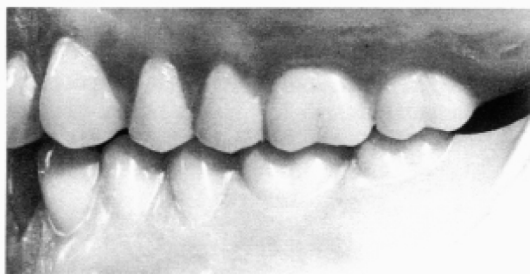

Figure 36

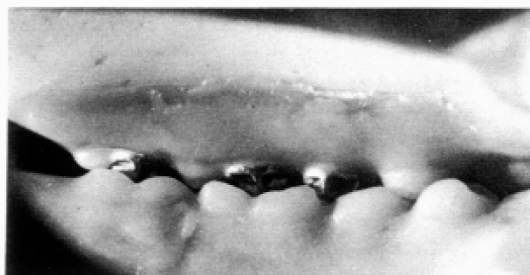

Figure 37

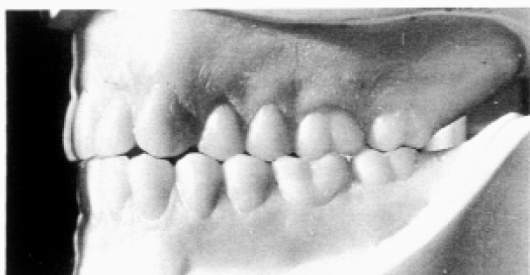
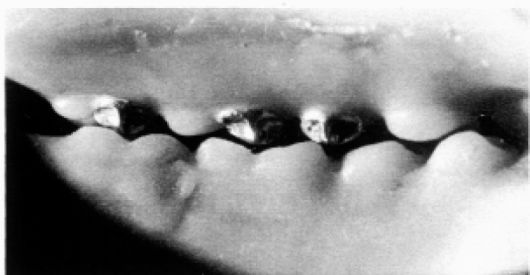
Figure 38



Set the maxillary second molar so it articulates with the lower. The mesio-lingual blade will fit into the specially designed fossa of the lower molar. The teeth should be in firm contact in the centric relation position. Figures 35 and 36 show the centric relation occlusion from the buccal and lingual view.

10

Figures 37 and 38 show the working-side balanced occlusion from the buccal and lingual view.

Figure 39

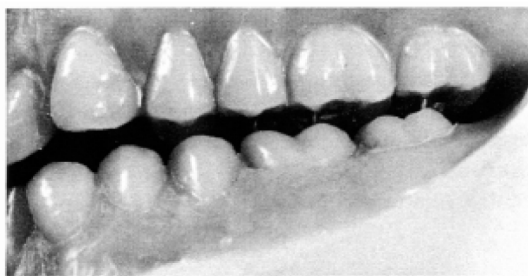

Figure 40

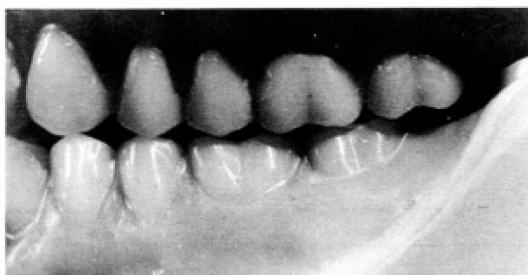

Figure 41

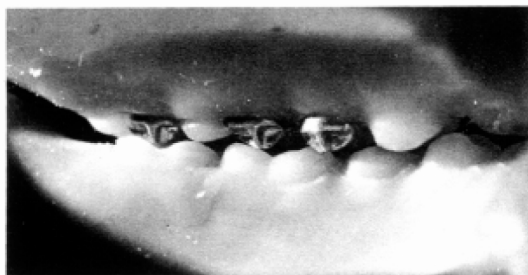

Figure 39 shows the balancing-side balanced occlusion from the buccal view.

Figures 40 and 41 show the protrusive balanced occlusion from the buccal and lingual view.

Set the teeth on the other side in the same manner. The teeth may be set simultaneously on both sides if that is more convenient. Either method will produce identical results. After all the teeth have been articulated, it is often necessary to do a small amount of grinding in order to perfect the occlusion. Milling paste can be used with complete confidence as no wear will occur on the cast blades.

11

Lingualized Occlusion

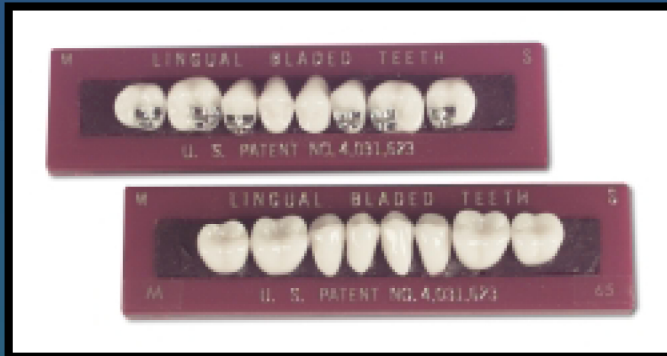
A popular form of cusp occlusion, introduced by Payne¹⁰, is called lingualized occlusion. In this form of occlusion, the buccal cusps do not contact and all the function is performed by the maxillary lingual cusps in the opposing fossae. The teeth must be modified by grinding when this form of occlusion is used. Lingual Bladed Teeth are ideal for this purpose as they are easy to modify and the functioning cusps have efficient cross-blades.

Monoplane Occlusion

Another popular form of occlusion is called monoplane or flat occlusion. This type of occlusion uses monoplane or flat teeth. Some proponents make no effort to obtain balance and others obtain some balance with the use of a compensating curve or a balancing ramp. This concept can be utilized with the bladed teeth by using flat teeth on the lower arch.

References

1. Black, C. V.: Physical Characteristics of the Human Teeth to Their Diseases, and in Practical Dental Operations, Together With the Physical Characteristics of Filling Materials, *Dent. Cosmos* 37:469-484, 1895.
2. Manley, R. S.: Factors Affecting Masticatory Performance and Efficiency Among Young Adults, *J. Dent. Res.* 30:874-882, 1952.
3. Kapur, K. and Soman, S.: Masticatory Performance and Efficiency in Denture Wearers, *J. Prosthet. Dent.* 14:687-694, 1964.
4. Hardy, I. R.: Developments in the Occlusal Patterns of Artificial Teeth, *J. Prosthet. Dent.* 1:14-28, 1951.
5. Rice, W. S.: A Mechanical Tooth Based on a New Principle, *CAL* 16:2-4,23-24, 1953.
6. Bader, W. A.: The Cutter Bar Technique, *Dent. Digest* 63:65-67, 1957.
7. Sosin, M. B.: Re-Evaluation of Posterior Tooth Forms for Complete Dentures, *J. Prosthet. Dent.* 11:55-61, 1961.
8. Levin, B.: A Review of Artificial Tooth Forms Including a Preliminary Report on a New Posterior Tooth, *J. Prosthet. Dent.* 38:3-15, 1977.
9. Frush, J. P. and Fisher, R. D.: Introduction to Dentogenic Restorations, *J. Prosthet. Dent.* 5:586-595, 1955.
10. Pound, E.: Esthetic Dentures and Their Phonetic Values, *J. Prosthet. Dent.* 1:98-111, 1951.
11. Payne, H. S.: A Posterior Set-Up to Meet Individual Requirements, *Dent. Digest* 47:20-22, 1971.



The Lingual Bladed teeth shown in this booklet are sold by



Justi Products

A Product Division of American Tooth Industries

1200 Stellar drive • Oxnard, CA 93033-2404 USA
(800) 235-4639 • (805) 487-9868 • FAX (805) 483-8482
E-MAIL: info@americantooth.com • WEB SITE: www.americantooth.com
Group/Item # 077-65-0057